

Histopathology Study Of A Cutaneous Leiomyosarcoma With Different Stain Techniques In Dog (Case Report)

Alketa Qoku

Department of Clinical Subject, Faculty of Medicine
Veterinary, Agriculture University of Tirana
Tirana, Albania
qoku.alketa@yahoo.it

Luljeta Dhaskali

Department of Clinical Subject, Faculty of Medicine
Veterinary, Agriculture University of Tirana
Tirana, Albania
lulidhaskali58@gmail.com

Abstract—Leiomyosarcomas are the most frequent malignant tumors of smooth muscles in dog. They are characterized as invasive nodules with mesodermal origin. Our study was carried out during the period January 2015-September 2015. The aim of this study was to use of different stain techniques to characterize histological features of the leiomyosarcoma and to differentiate it with similar tumors like as Schwannoma, malignant fibrohistiocytoma, etc. The special stain techniques (Malloy's Trichrome, Toluidine Blue pH4.5, Pears Van Gieson and Periodic Acid-Schiff), used to evidence the neoplastic architecture and relationship according with surrounding tissues. Histopathological examination showed a tumor composed of pleomorphic spindle to ovoid cells forming interlacing bundles and variably dense fibrous connective tissue separated by streams of neoplastic cells. These techniques identify the specific connective tissue for interesting structures.

This case report to give a short information about of the using of a pannel of stains in order to make in evidence histological changes of muscles and cells in a perianal area tumor in a dog.

Keywords—dog, leiomyosarcoma, biopsy, histopathology

I. INTRODUCTION

Mesenchymal tumors are known as soft tissue tumors. These tumors have different appearances and histological behavior [4]. Leiomyosarcoma (LMS) is a rare form of cancer and accounts for 5-10% of soft tissue sarcomas [5, 8, 9]. Leiomyosarcoma, as smooth muscle tumor, also, it can be found in the wall of the blood vessels, the pili-erector muscles, in the smooth muscles of the vagina, vulva, perianal skin etc, [5]. It is typical in older dogs and that has the potential to metastasize to other organs. The average age of the appearance of these tumors in canine was 10.5 years old. The breeds with high risk are large-breed

dogs such as Golden Retriever, Saint Bernard, and Doberman Pincher, etc. However, many authors point out that there is no correlation between age and breed dog for appearance of this pathology [1]. Leiomyosarcoma, as a soft tissue tumor, is often difficult to differentiate with malignant fibrohistiocytoma, fibrosarcoma or benign Schwannoma, because of similarities of their histological features.

The use of staining techniques that evidence the conjunctive tissues can be helpful to make the differentiation of the nature of leiomyosarcoma with other forms of similar to it.

The stain techniques to used in this study were Malloy Trichrome, Pears Van Gieson, Toluidine Blue and immunohistochemistry techniques Periodic Acid-Schiff. Malloy's Trichrome and Pears Van Gieson staining techniques make in evidence the difference between muscle cells to surrounding connective tissue. Toluidine Blue also used for highlighting the mitotic figures. Periodic Acid-Schiff (PAS) technique was used to identify glycogen and amylase, if it is present.

The aim of this study was the use of different techniques to characterize histological features of the leiomyosarcoma and to differentiate it with similar tumors like as Schwannoma, malignant fibrohistiocytoma, etc.

II. MATERIALS AND METHODS

Specimens of a subcutaneous malignant leiomyosarcoma in perianal region of a dog, submitted to Small Animal Clinic at Faculty of Veterinary Medicine, Agricultural University of Tirana, Albania, were included in this case report. The dog was 10 years old, male sex and mix breed. For histopathologic examination, a piece of tissue was fixed in 10% neutral buffered formalin, paraffin embedded, and sectioned at 5 µm thickness. The tissues were deparaffinized in xylene, rehydrated in 100%, 95%, and 70% alcohol (twice, 4 min each), and washed in distilled water. Biopsied subcutaneous tissue was processed and stained by Gill's Hematoxylin (H&E) (Merck – Darmstadt – Germany), standard histopathological

method [10]. Sections of tumor were also stained with different techniques. Malloy's Trichrome and Pears Van Gieson (specific for differentiating muscle cells from collagen fibers), Toluidine Blue pH 4.5 (Merck) to highlight the mitosis, and Periodic Acid-Schiff (PAS) to identify glycogen and amylase, were applied.

Sections of the leiomyosarcoma were observed under the MOTIC, BA 210 microscope.

III. RESULTS AND DISCUSSION

Leiomyosarcoma is a malignant tumor of smooth muscle cells that can arise almost anywhere in the body, but it is most common in the uterus or abdominal organs [5, 9, 4]. Some reports describing subcutaneous leiomyosarcomas in humans, dogs, cats, ferrets and monkeys [7, 12].

Our case study presents a spontaneous leiomyosarcoma from smooth muscle in the perianal region, based on the macroscopic and histological features. The dog was 10 years old, of male sex and mix breed. This is a rare case of leiomyosarcoma.

An objective to diagnose different changed structures on a case report of a leiomyosarcoma is to use a panel of different stain techniques.

H-E technique, as a routine important tool, and different stain techniques are using to characterize histological features of the leiomyosarcoma. On the other hand the purpose of it was to differentiate it with similar malignant tumors such as, malignant fibrohistiocytoma, Schwannoma etc.

Serial sections (5 µm thick) were stained by a panel of histological stains included H-E, Malloy's Trichrome, Pears van Gieson (PVG), Toluidine Blue pH 4.5 (TB) and Periodic Acid – Schiff (PAS).

Microscopic diagnostic parameters in the tumor are: cell type differentiation, mitotic index, presence of areas of necrosis, tumor margins appearance and relationship with adjacent structures.

The sample stained with H & E technique of malignant well-differentiated leiomyosarcoma showed the presence of pleomorphic cells with fusiform aspect, a small cytoplasm and nucleus and they are organized in groups. The tumor was composed of muscular spindle cells with elongated shaped nuclei and abundant eosinophilic cytoplasm which was arranged in interweaving fascicles [Figure 1].

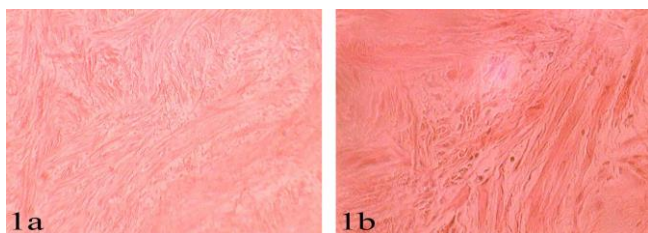


Figure 1: Canine Leiomyosarcoma: spindle cells show pleomorphisms (H and E stain, Obj. A) X100 and b) X400)

The histological features were further confirmed by using Masson's Trichrome stain (MTS) which stained the smooth muscles pink [figure 2].

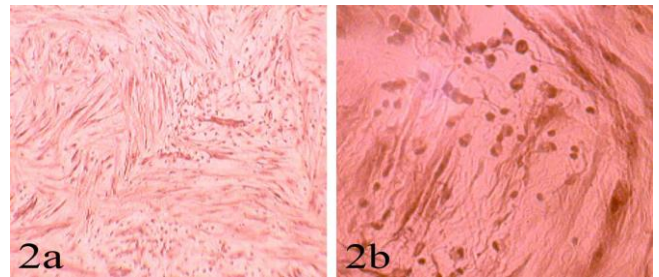


Figure 2: Canine Leiomyosarcoma: Area with dense conjunctive fibers and few fusiform cells. (Mallory's Trichrome, Obj. A) X100 and b) X400)

The Pears Van Gieson staining technique is used to differentiate collagen and smooth muscle in soft tissues tumors and to demonstrate the increase of collagen in it. Masson's Trichrome connective tissue stain and Pears Van Gieson's collagen fiber stain revealed collagen bundles in the tumor area [5]. The cytoplasm of neoplastic cells stained red with Masson's trichrome stain and yellow with Pears van Gieson's stain [Figure 3].

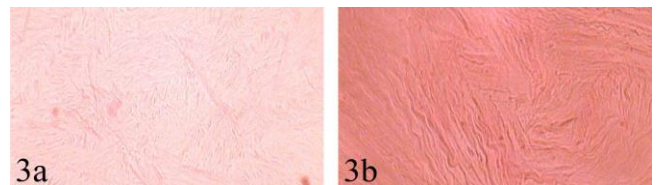


Figure 3: Canine Liomyosarcoma: Demonstrate collagen fiber stain bundles in the tumor area. (Pears Van Gieson). A) X100 and b) X400).

Toluidine Blue stain presents low capacity of distinction from the conjunctive tissue. According to A. M. Magalhães [2] and W. C. Rocha et al., [14] this stain is very important in order to characterize not only factors related to cutaneous carcinoma but also to evidences mastocytes. There were observed the cellular and nuclear pleomorphism in figure 4. The chromatin is not well evident by other stain technics.

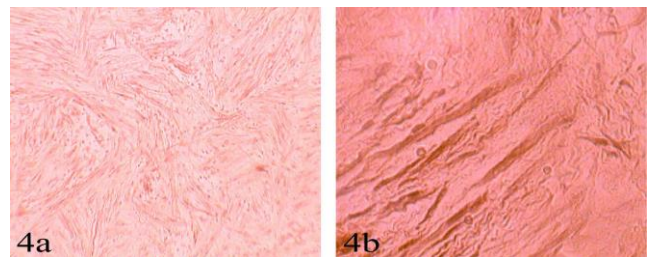


Figure 4: Canine Liomyosarcoma: Fusiforme cells disposed in bands (Toluidine Blue, Obj. A) X100 and b) X400).

It is not evident the marked positivity for glycogen and amylase in the neoplastic cells stain with Periodic Acid-Schiff stain.

The histopathological features of the leiomyosarcoma in the presented case were similar to those described in the genital system and other organ systems of different species with highest frequency in dogs and cats. In these species the tumor was composed of proliferating elongated cells forming interlacing bundles and streams [3, 6, 11, 13]. No metastases were found in our patient, in accordance with clinical signs. These different stain techniques made possible the differentiation of leiomyosarcoma and another

similar tumors. Tumor showing differentiation towards smooth muscle include benign tumors, and malignant ones.

However, based on the results of this case, it is necessary to enlarge the knowledges about of different stained techniques to the malignant neoplasm diagnosis, because it could been used in the differentiation of the it.

IV. CONCLUSION

Tumor mass within the smooth muscle of a dog was diagnosed as leiomyosarcoma based on histopathological features, and might represent the first description of canine perianal skin leiomyosarcoma in our country.

In conclusion, the deep variant of liomyosarcoma (LMS) in the dog can be regarded as a highly malignant, rapidly invasive neoplasm of the soft tissues that is similar in appearance and behavior to its counterpart in humans.

Hematoxylin & Eosin staining, the leiomyosarcoma can be mistaken for another neoplasm. Some special staining in LMS are used to differentiate histologic types of neoplastic lesions in our case. So, the routine of practice in diagnosing leiomyosarcoma is to use a panel of different stain techniques.

Based on the reported case, it will be necessary to use these techniques for the differentiation of other forms of malignant neoplasms.

We hope that this case report about a leiomyosarcoma of the perianal region in a dog diagnosed by a pannel of stain techniques serves to enrich the bibliografy of neoplasms in dog.

V. REFERENCES

- [1] A. Florin Gal, A. Andriopoulou, V. Miclăus, F. Tăbăran, M. Taulescu, A. Nagy, Vasile Rus, Roxana Cora, R. Vidrighinescu, C. Cătoi, "Comparative Data Concerning the Incidence of Tumors in Dogs in a Period of Ten Years in Athens (Greece) and Cluj-Napoca (Romania)", *Bulletin UASVM Veterinary Medicine*, 72(2); pp. 371-377, 2015.
- [2] A. M. Magalhães, "Estudo comparativo entre citopatologia e histopatologia no diagnóstico de neoplasias caninas". *Pesquisa Veterinária Brasileira*, Rio de Janeiro, 21(1); pp. 23-32, 2001.
- [3] B. J. Cooper, B. A. Valentine, "Tumors of muscle", In: Meuten DJ (ed.): *Tumors in Domestic Animals*. 4th ed. Iowa State Press, Iowa 2002, pp. 319–363.
- [4] F. M. Enzinger, S. W. Weiss, J. R. Goldblum, "Soft Tissue Tumors". 4th ed., Mosby Year Book, St Louis, MO, 2001, pp. 741–744.
- [5] G. Serin, A. Aydogan, R. Yaygingul, R. Tunca, "Uterine leiomyosarcoma in a dog: a case report" *Veterinarni Medicina*, 2010. 55: (8), pp. 405–408.
- [6] I. Firat, D. Haktanir-Yatkin, B. H. Sontas, H. Ekici, "Vulvar leiomyosarcoma in a cat", *Journal of Feline Medicine and Surgery*, 2007, pp. 435–438.

- [7] J. K. Park, IH Hong, MJ Goo, MR Ki, KS Hong, OK Hwang, JY Han, AR Ji, SI Park and KS Jeong, "Subcutaneous leiomyosarcoma in an adrenomedullin heterozygous mouse". *Exp Toxicol Pathol* 2010, 62: pp. 221- 225
- [8] J. M. Liptak, L. J. Forrest, "Soft tissue sarcomas" In: Withrow, SJ, and Vail, DM, eds. *Withrow & Macewen's Small Animal Clinical Oncology*. 4th ed. St. Louis: Saunders Elsevier, 2007, pp. 425-454.
- [9] K. C. Lee, M. S. Kim, H. Choi, CH. Na and B. S. Shin, "Rapid growing superficial cutaneous leiomyosarcoma of the face". *Ann Dermatol*, 25: pp. 237-241. 2013.
- [10] L. G. Luna, "Manual of histological staining methods of armed forces institute of pathology". Washington: McGraw Hill 1968.
- [11] N. J. MacLachlan, P. C. Kennedy, "Tumors of the genital system". In: Meuten DJ (ed.): *Tumors in Domestic Animals*. 4th ed. Iowa State Press, Iowa 2002, pp. 547–573.
- [12] S. I. Nakamura, S. Iseda and Y. Une, "Subcutaneous leiomyosarcoma in a common squirrel monkey (*Saimiri sciureus*)". *J Vet Med Sc* 2010, 72: pp. 639-642.
- [13] T. Sato, K. Aoki, H. Shibuya, T. Machida, T. Watari 2003. Leiomyosarcoma of kidney in a dog. *Journal of Veterinary Medicine Series A*. 50; pp. 366–369.
- [14] W. C. Rocha, C. S. Lorandi, E. F. Mendonça, "Uso do azul de toluidina como método auxiliarna detecção de displasias epiteliais e carcinomas da mucosa bucal", *Revista Odonto Ciência*. 11(21); pp. 27-48, 1996.